Neuropathic corneal pain (NCP)

Seyyed Hashem Daryabari, MD

Associate Professor of Ophthalmology

Baqiyatallah University of Medical Sciences

- The International Association for the Study of Pain defines neuropathic pain as "**pain initiated or caused by a primary lesion or dysfunction of the nervous system**"

- Neuropathic pain can also occur in the cornea, the most richly innervated tissue in the body.

- Neuropathic corneal pain (NCP) remains an illdefined entity (also termed corneal neuralgia, keratoneuralgia, corneal allodynia, or corneal neuropathy.

- can be perceived as pain, discomfort, aching, photoallodynia, burning, irritation, dryness, and grittiness, symptoms that may overlap with diseases such as dry eye disease (DED).

pathophysiology of Neuropathic Corneal Pain

- the sensory nervous system consists of sensory neurons, neural pathways, and the sensory cortex.

- Nociceptors are receptors necessary for pain perception, and they may generate action potentials to thermal, mechanical, chemical, or polymodal (more than 1) stimuli.

- NCP may have a:
- **peripheral origin** (e.g., ocular surgery (R.S)or herpes zoster ophthalmicus)
- or a **systemic origin** (e.g., small-fiber polyneuropathy or fibromyalgia
- **Mix**

Table 1. Etiology of Neuropathic Corneal Pain

1. Ocular Diseases
   - Dry eye disease[4–6,12]
   - Infectious keratitis[13]
   - Herpetic keratitis[23,38]
   - Recurrent erosion syndrome[13]
   - Radiation keratopathy[13]
   - Trauma[4]
2. Postsurgical
   - Refractive surgery[6,9]
   - Cataract surgery[5]
3. Systemic diseases
   - Small-fiber polyneuropathy[4,6]
   - Fibromyalgia[4,6]
   - Trigeminal neuralgia[5]
   - Medication-induced neuropathy (chemotherapy)
   - Autoimmune conditions (Sjögren's syndome, lupus, sarcoidosis, inflammatory bowel disease, celiac disease)[4]
   - Diabetes[4,14]
   - Oculofacial pain[5]
4. Comorbidities
   - Anxiety[12]
   - Depression[12,69]
   - Posttraumatic stress disorders[12]

diagnosing Neuropathic Corneal Pain

- NCP is typically diagnosed based on *clinical history*, *symptoms,* ophthalmologic *examination*, and *evidence of nerve injury* (by in vivo *confocal microscopy* [IVCM]) and/or nerve dysfunction (nerve function tests)

- Patients typically complain of prolonged dry eye treatment, experience multiple treatment failures, note an inciting event (e.g., infection or surgery), and may complain about nonocular pain, neurologic, or psychiatric.

- **ocular Pain Questionnaires to Assess Symptoms:**
- OSDI
- McMonnies Dry Eye Questionnaire,
- Ocular Pain Assessment Survey (OPAS)
- Neuropathic Pain Symptom Questionnaire

Functional Somatosensory Testing

- the Proparacaine Challenge Test
- Corneal Esthesiometry
- Clinical Examination
- In Vivo Confocal Microscopy to Confirm Corneal Nerve Damage.

Functional Somatosensory Testing

- **the Proparacaine Challenge Test**:
- Establishing the origin of pain, whether central or peripheral, is important for selecting appropriate treatment measures.
- Topical 0.5% proparacaine hydrochloride allows for differentiation of central from peripheral sources of pain
- patients experiencing complete or partial relief with proparacaine challenge likely suffer from peripheral or mixed combined NCP.

- It is however important to highlight that the proparacaine challenge test cannot distinguish between patients with pathologic dry eye symptoms and patients with peripheral symptoms of neuropathic origin

- We believe that patients with signs of DED may also present with symptoms of NCP.

- However, no tests are currently available to distinguish between these entities.

- Corneal Esthesiometry Direct somatosensory measurement using esthesiometers, such as the Cochet Bonnet contact esthesiometer.

- A recent study has demonstrated that patients with severe dry eye or neuropathic pain symptoms present with increased corneal sensitivity, while another study has shown decreased corneal sensitivity in patients with DED.

- **Clinical Examination**: fluorescein test, TBUT Schirmer's test ,tear osmolarity

- patients with NCP often present with symptoms out of proportion to signs and may demonstrate minimal signs on slit-lamp examination.

- **In Vivo Confocal Microscopy to Confirm Corneal Nerve Damage**:

- in patients with NCP have demonstrated decreased corneal nerve density associated with allodynia, photoallodynia, and post-LASIK neuralgia.

- the presence **of microneuromas** by IVCM in these patients have been shown to be **specific for NCP**.

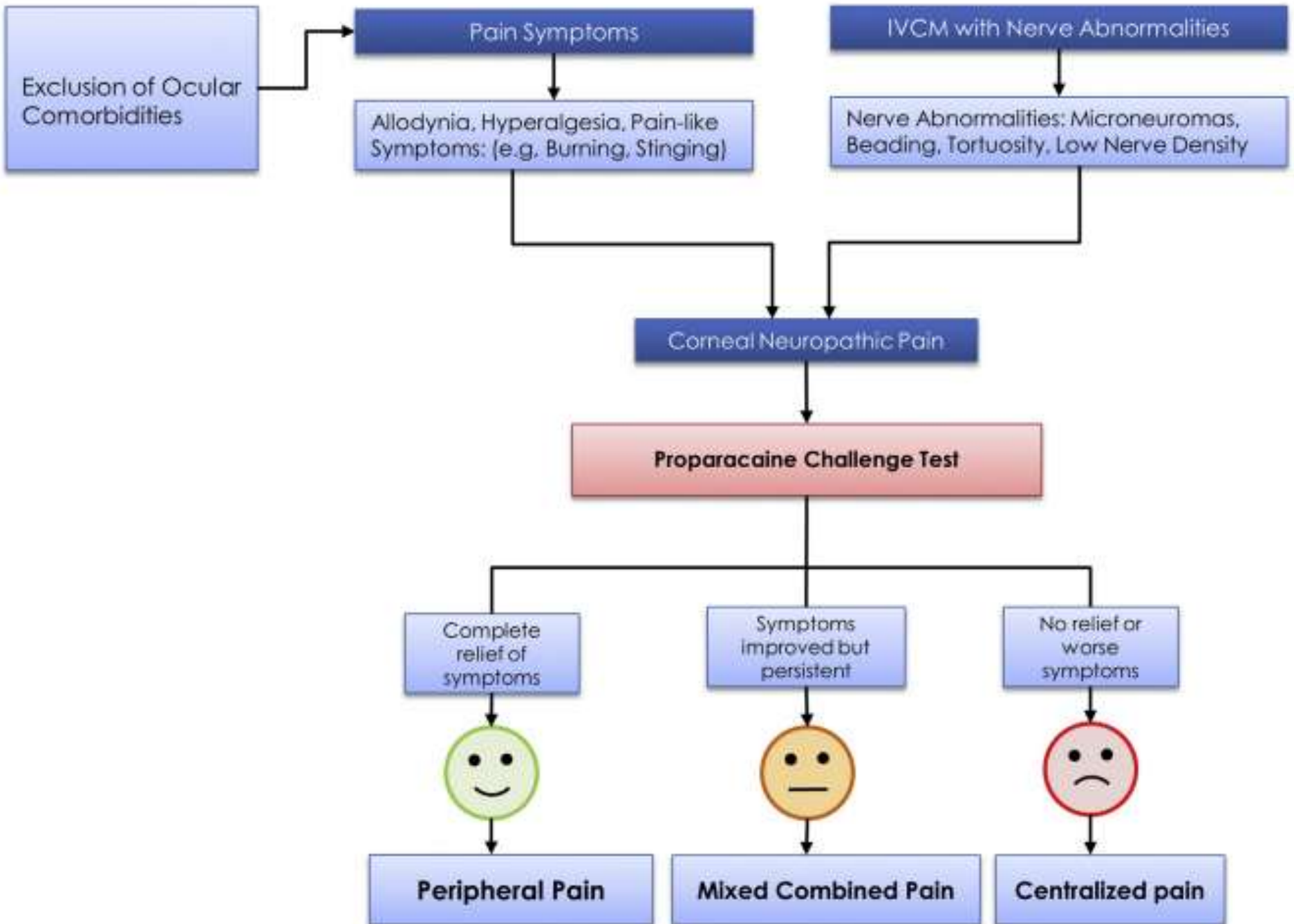
Exclusion of Ocular Comorbidities
Pain Symptoms
Allodynia, Hyperalgesia, Pain-like Symptoms: (e.g. Burning, Stinging)
IVCM with Nerve Abnormalities
Nerve Abnormalities: Microneuromas, Beading, Tortuosity, Low Nerve Density
Corneal Neuropathic Pain
Proparacaine Challenge Test
Complete relief of symptoms
Symptoms improved but persistent
No relief or worse symptoms
Peripheral Pain
Mixed Combined Pain
Centralized pain

therapeutic Strategies for NCP

- devising management strategies for NCP patients requires differentiation of peripheral, mixed, and centralized sources of pain

- **neuroregenerative Therapy**:

- autologous serum tears(NGF) ,platelet-rich plasma.

- Recovery of corneal nerve mapography has been demonstrated with the use of AST in patients with NCP

- In NCP patients, we have demonstrated significant improvement of symptoms of allodynia, and photoallodynia with 20% AST within 3.6 months of treatment

- 20% AST 8 times daily, , followed by a very slow taper(9-12 m)

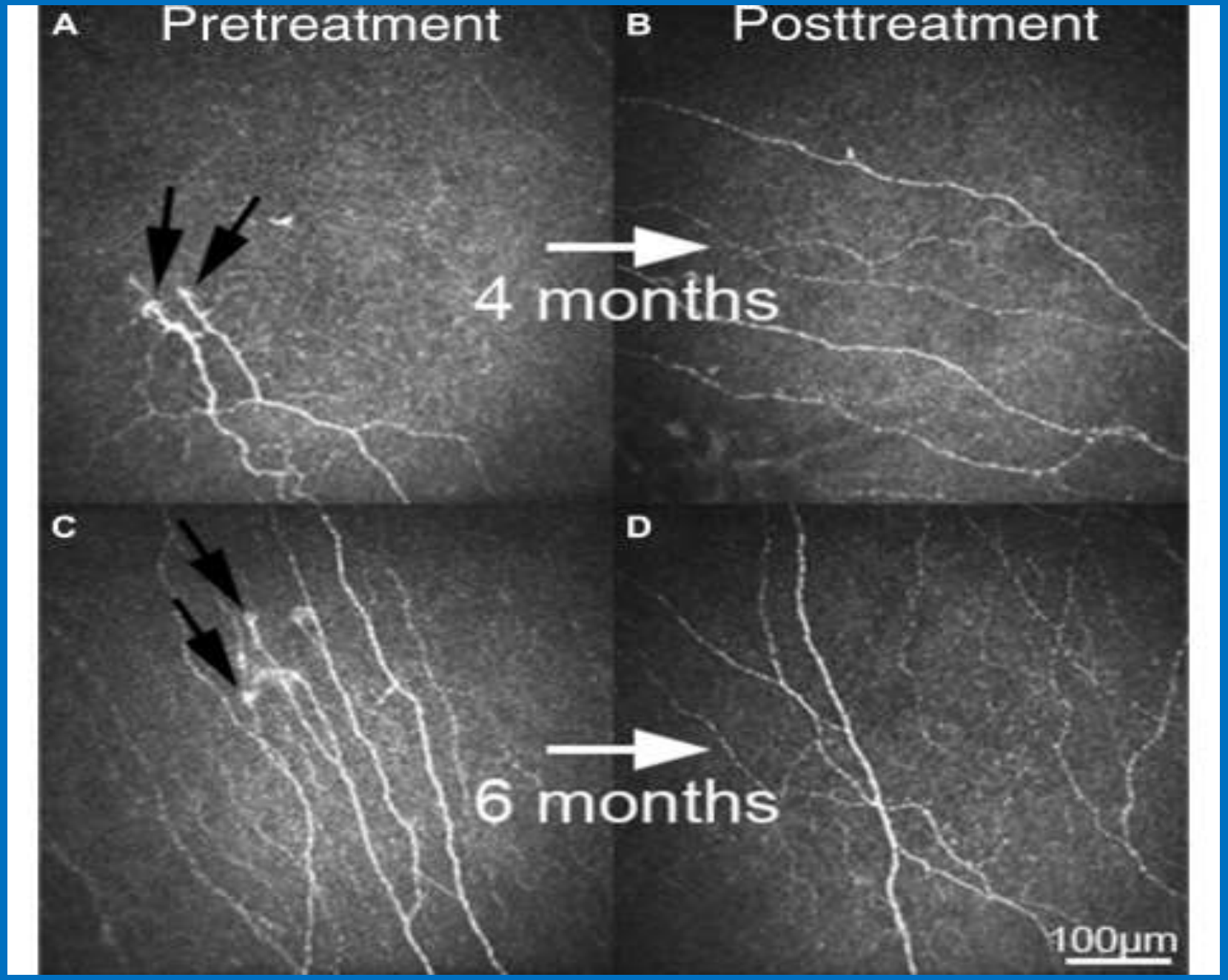
A
Pretreatment
B
Posttreatment
4 months
C
D
6 months
100µm

- **Anti-Inflammatory Therapy**:

- The critical role of inflammation in the pathophysiology of NCP provides the rationale for the use of anti-inflammatory therapy.

- use of low-dose topical corticosteroids(loteprednol 0.5%)(with AST) resulted in significant increase in corneal nerve regeneration as compared with AST alone.

- we recommend use of loteprednol 0.5% suspension or gel with a slow taper of 4 times daily for 2 weeks, followed by twice daily for 2 weeks and once daily over a 6- to 12- week period.

- **Steroid sparing therapies** such as topical calcineurin inhibitors **cyclosporine A 0.05**% 2 to 4 times daily, **tacrolimus 0.03%** 3 times daily, the interleukin-1 receptor antagonist anakinra (Kineret) 2.5% 3 times daily, and topical **testosterone 0.03%** 3 times daily.

- **Ocular Surface Rehabilitation and Managing Comorbidities**.
  :
- Palliative treatment with lubrication of the ocular surface can provide additional short-term relief for patients with NCP.

Table 2. Topical Treatments for Neuropathic Corneal Pain

Topical Agent	Mechanism of Action	Pathology	Efficacy, Level of Evidence
Autologous serum tears 20%	Neurotrophic factors: NGF, substance P, insulin-like growth factor-1	Injured nerves and epithelial cells	MLE, Levels 3 and 4[6,44,50–63]
Corticosteroids (e.g., loteprednol 0.5%)	- Anti-inflammatory - Inhibit leukocyte migration - Inhibit cytokines, prostaglandin, and leukotriene synthesis	Ocular surface inflammation	HLE, Level 1[75–81]
Cryopreserved amniotic membrane	- Anti-inflammatory - Neurotrophic factors	Ocular surface inflammation	MLE, Level 3[94–99]
Bandage contact lens, scleral lens	- Protective effect against the environmental triggers	Ocular surface injury	MLE, Level 2[103–108]
Artificial tears (preservative-free, emulsion-based)	Decrease tear osmolality – dilution Protective mechanism in evaporative dry eye	Ocular surface disease	HLE, Level 1[89]

HLE = high level of evidence; MLE = medium level of evidence; NGF = nerve growth factor.

- **Systemic Pharmacotherapy**.
- Symptoms of NCP can present owing to central sensitization In these cases, systemic pharmacotherapy is required for pain relief.
- In addition, systemic therapies may aid in treatment of peripheral sensitization and result in accelerated relief.
- **first-Line Agents**.
- Tricyclic Antidepressants. 25 to 150 mg amitriptyline daily in PHN.

Table 3. Systemic Pharmacotherapy for Neuropathic Corneal Pain

Medication (Class)	Mechanism of Action	Starting Dosage	Maximum Dosage	Side Effects	Precautions and Contraindications
First-line agents					
Nortriptyline, desipramine (Tricyclic antidepressants) Use a tertiary amine TCA only if a secondary is not available[112–119] Nortriptyline/desipramine are FDA-approved for treatment of symptoms of depression	Monoamine reuptake inhibition, sodium channel blockade, and anticholinergic effects	10–25 mg at bedtime	100 mg at bedtime	Dry mouth, constipation, somnolence, anticholinergic effects, weight gain	Cardiac disease, prostatic adenoma, and seizure disorder High doses should be avoid in adults >65 years of age
Carbamazepine (anticonvulsant)[120,121] FDA-approved for epilepsy, trigeminal neuralgia, and manic and mixed episodes of bipolar disorder	Sodium channel blocker	200 mg daily	400–800 mg/day, divided in 2–3 doses	Hyponatremia, drowsiness, headache, dizziness, rash, and nausea	Concomitant use of MAO inhibitors Cardiac or hepatic disease Renal failure Prostatic hyperplasia
Second-line agents					
Low-dose naltrexone (opioid antagonist)[122–124] FDA-approved at higher doses (50–300 mg) for treatment of drug and alcohol addiction	At low doses has an anti-inflammatory effect, reducing the proinflammatory cytokines Modulating microglial activity Opioid antagonist –: μ-opioid and κ-opioid receptors	1.5 mg at bedtime	4.5 mg at bedtime	Headache, vivid dreams, nightmares, tachycardia, and anxiety	Past organ transplant and use of immunosuppressive drugs
Tramadol (opioid agonist)[110,111,125] FDA-approved for treatment of moderate to moderately severe pain	μ-Receptor agonist and monoamine reuptake inhibitor	50 mg/day	100 mg/day in divided doses every 3–7 days as tolerated	Nausea, vomiting, constipation, dizziness, and somnolence	History of substance abuse, suicide risk, and antidepressant use in elderly patients

Third-line agents					
Calcium channel $\alpha_2\delta$ ligands Gabapentin (anticonvulsants) FDA-approved for treatment of postherpetic neuralgia Pregabalin (anticonvulsant)[113,126–136] FDA-approved for treatment of neuropathic pain and fibromyalgia	Act on the $\alpha_2\delta$ subunit of voltage-gated calcium channels, which decrease central sensitization	100–300 mg 3 times per day 50 mg 3 times per day or 75 mg twice daily	2400 mg/day 300 mg/day	Sedation, dizziness, peripheral edema	Reduced dose in renal insufficiency
(Serotonin-noradrenaline reuptake inhibitors) Duloxetine[137–139] FDA-approved for treatment of diabetic peripheral neuropathic pain and fibromyalgia	Serotonin-noradrenaline reuptake inhibitors	30 mg/day	60 mg twice per day	Nausea, abdominal pain, constipation	Hepatic disorders Use of tramadol Hypertension
Mexiletine (sodium channel blocker)[140] FDA approved for treatment of cardiac arrhythmia	Voltage-gated sodium channel blocker Lidocaine analogue Class IB antiarrhythmic	225–675 mg/day	675 mg/day	Nausea, headache, sleep disturbances, tiredness Gastritis is the most common side effect	Hepatic impairment Severe heart failure Sinus node dysfunction or intraventricular conduction defect

- **lifestyle Changes**:.
- Preclinical and clinical evidence suggests efficacy of c**ardiovascular exercise** in pain relief through inhibition of pain pathways that alter pain perception, resulting in improvement of allodynia and hyperalgesia.

- We recommend trials of cardiovascular exercise for at least 30 minutes twice weekly.
- Nutritional intervention strategies(**omega 3**)

- acupuncture
- noninvasive transcranial magnetic stimulation (TMS)
- intrathecal drug delivery

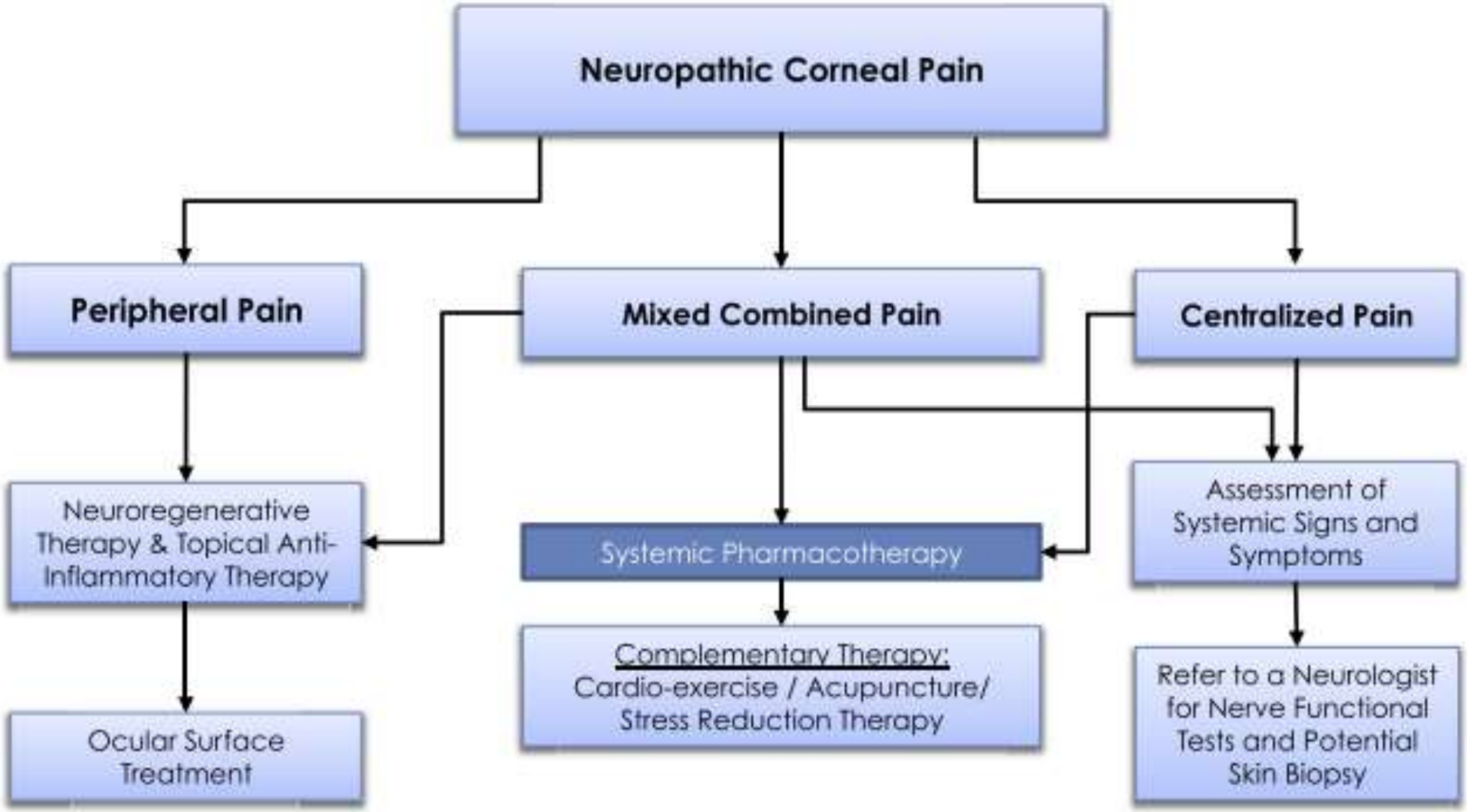
Neuropathic Corneal Pain
Peripheral Pain
Mixed Combined Pain
Centralized Pain
Neuroregenerative Therapy & Topical Anti-Inflammatory Therapy
Systemic Pharmacotherapy
Assessment of Systemic Signs and Symptoms
Ocular Surface Treatment
Complementary Therapy: Cardio-exercise / Acupuncture/ Stress Reduction Therapy
Refer to a Neurologist for Nerve Functional Tests and Potential Skin Biopsy

Summary

- The management of patients with NCP remains extremely challenging in clinical practice, although much progress has been made, resulting in increased awareness, diagnostics, and treatments of these patients.

- No single therapy will likely be successful and combination therapy will remain the mainstay of treatment, addressing the various and complex underlying factors in this disease.

- **Case**:Corneal Neuropathy After LASIK Surgery (PostLASIK Neuralgia)
- a 35-year-old healthy male, was referred for ocular pain and dry eye symptoms in both eyes.
- PMH:Neg.
- LASIK surgery in both eyes performed 10 years ago.
- Two years post-LASIK, he started noticing ocular pain.
- He had been to several different ophthalmologists.
- A diagnosis of dry eye disease was made, and he was given artificial tears and steroid eye drops, both of which provided no relief.
- A different ophthalmologist diagnosed scleritis. He took prednisone 60 mg per day for 1 week, which reduced the pain. He then switched to naprosyn 250 mg twice daily, and the pain returned.
- An MRI of the brain and orbits was performed which was normal.
- .He was on prednisolone acetate drops, vitamin C tablets, Omega-3, B complex vitamins, and calcium. His
- visual acuity was 20/20 in the both eyes.
- Slit-lamp examination revealed mild blepharitis, normal LASIK flaps, and no corneal staining. The rest of the ocular exam was also normal.

- In this patient, IVCM examination revealed an increase in the presence of dendritic cells, neuromas, and nerve tortuosity, while also revealing a reduction in nerve density

- A diagnosis of corneal neuropathy was made. The pain was significantly reduced with proparacaine drops, confirming the theory of peripheral corneal neuropathy following LASIK surgery

- The patient was prescribed autologous serum tears (20%) eight times a day

and loteprednol etabonate 0.5% drops four times a day for a week, tapering to a drop each week.

- After 6 months, the patient reported significant resolution of his symptoms and occasional flare-ups.

- Ocular examination was normal, and IVCM revealed no neuromas but persistent inflammation with a maintained reduction of nerve density The previous treatment was maintained.

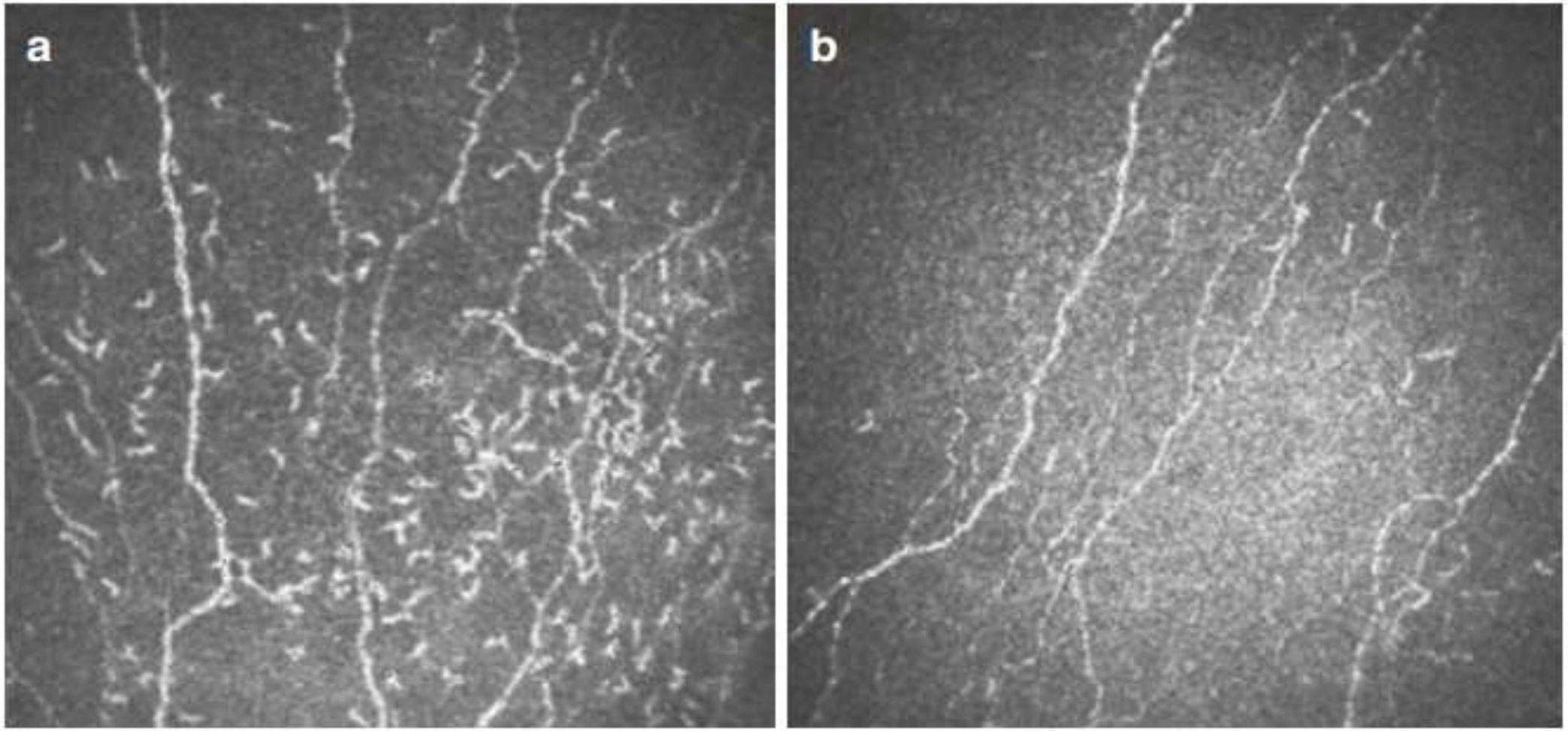

Fig. 8.2 IVCM examination of a patient with corneal neuropathy and inflammation. At the beginning of the follow-up, IVCM showed a marked increase in dendritic cell density and a significant reduction in the nerve density (**a**). At 6 months, IVCM revealed a substantial decrease in dendritic cells and a moderate increase in the nerve density (**b**)

Case 2 : Ocular Pain and Centralized Pain

- A 70-year-old female was referred with a diagnosis of filamentary keratitis and photophobia.
- She was followed for 2 years elsewhere with partial response to removal of filaments with forceps and the use of bandage contact lenses.
- She had received punctal plugs and topical steroids with limited improvement.
- At her first examination, she was taking cyclosporine 0.05% drops four times daily
- The pain interfered with driving, watching TV, and sleeping.
- She had mild blepharitis, with partial occlusion of meibomian gland ducts.
- The central cornea showed PEK and few central debris filaments.
- TBUT was abnormally rapid, and tear meniscus was reduced.

- VCM showed neuromas in both eyes, high corneal nerve tortuosity, and a reduction of corneal nerve density
- Proparacaine drops did not provide relief from pain.
- A diagnosis of corneal neuropathy associated with central pain was made.

- The patient was started on autologous serum tears 20% eight drops a day,
- loteprednol etabonate 0.5% drops four drops a day for a week, tapering to a drop each week,
- and carbamazepine 400 mg orally twice daily.

- After 6 months of the treatment, the patient reported a substantial improvement of his symptoms, with only occasional discomfort.
- IVCM at 6 months showed a reduction of dendritic cells compared to the first visit, as well as an increase in nerve density .
- Serum tears were maintained.

The END